

MODELLING MYELOABLATIVE CYTOSTATIC THERAPY WITH CYCLOPHOSPHAMIDE IS ACCOMPANIED BY GASTROINTESTINAL STASIS IN RATS

Schäfer TV¹✉, Ivnitsky JuJu², Rejniuk VL²

¹ State Scientific Research Test Institute of the Military Medicine of Defense Ministry of the Russian Federation, Saint-Petersburg, Russia

² Golikov Research Clinical Center of Toxicology of the Federal Medical Biological Agency, Saint-Petersburg, Russia

Cyclophosphamide is used for the treatment of lymphoma, leukaemia, some solid tumours, and autoimmune disorders. When carrying out myeloablative cytostatic therapy, the doses of cyclophosphamide are prescribed, which cause irreversible pancytopenia. Early toxic effects of such doses are manifested by asthenic and emetic syndromes, limiting the treatment tolerance. Administration of cyclophosphamide in a dose of ≥ 600 mg/kg is accompanied by hyperammonaemia and symptoms, specific to the acute ammonium salt intoxication. Endotoxemia, resulting from the increase in the intestinal barrier permeability due to the impaired gastrointestinal motility, is considered the possible mechanism underlying these phenomena. The study was aimed to test this hypothesis. Radiographic assessment of the rat gastrointestinal peristalsis was performed within 25 h after administration of cyclophosphamide in a dose of 1000 mg/kg, which was equivalent to myeloablative dose for humans. Intraperitoneal, subcutaneous or intragastric administration of cyclophosphamide slowed down the gastrointestinal transit of bariumsulfate. In the case of subcutaneous cyclophosphamide injection, a moderate effect was observed. In the case of cyclophosphamide administered by gavage, the effect was manifested by a complete halt of transit. Thus, modelling myeloablative cytostatic therapy with cyclophosphamide in rats is associated with gastrointestinal stasis. The changes reported may promote the entry of the gut microbial products into the bloodstream and ensuing endotoxemia.

Keywords: cyclophosphamide, myeloablative cytostatic therapy, rat model, radiography, gastrointestinal stasis

Author contribution: Schäfer TV — developing the experimental model, study planning, experimental procedure, data processing and visualization; Ivnitsky JuJu — rationale, developing the experimental model, data interpretation; Rejniuk VL — setting up the experiment. All authors contributed to discussion, manuscript writing and editing.

Compliance with ethical standards: the study was carried out in accordance with the principles of bioethics, approved by the European Convention for the Protection of Vertebrate Animals used for Experimental and Other Scientific Purposes (ETS N 123).

✉ **Correspondence should be addressed:** Timur V. Schäfer
Lesoparkovaya, 4, Saint-Petersburg, 195043; schafer@yandex.ru

Received: 14.12.2021 **Accepted:** 15.01.2022 **Published online:** 31.01.2022

DOI: 10.47183/mes.2022.001

МОДЕЛИРОВАНИЕ МИЕЛОАБЛЯЦИОННОЙ ЦИТОСТАТИЧЕСКОЙ ТЕРАПИИ ЦИКЛОФОСФАНОМ СОПРОВОЖДАЕТСЯ ЖЕЛУДОЧНО-КИШЕЧНЫМ СТАЗОМ У КРЫС

Т. В. Шефер¹✉, Ю. Ю. Ивницкий², В. Л. Рейнюк²

¹ Государственный научно-исследовательский испытательный институт военной медицины Министерства обороны Российской Федерации, Санкт-Петербург, Россия

² Научно-клинический центр токсикологии имени академика С. Н. Голикова Федерального медико-биологического агентства, Санкт-Петербург, Россия

Циклофосфан применяют для лечения лимфом, лейкозов, некоторых солидных опухолей и аутоиммунных заболеваний. При миелоабляционной цитостатической терапии его назначают в дозах, вызывающих необратимую панцитопению. Ранние токсические эффекты при таких дозах проявляются астеническим и эметическим синдромами, ограничивающими переносимость лечения. Введение циклофосфана крысам в дозах ≥ 600 мг/кг сопровождается гипераммониемией и симптоматикой, характерной для острой интоксикации солями аммония. Возможным механизмом этих феноменов является эндотоксемия, обусловленная повышением проницаемости энтерогематического барьера вследствие нарушений моторики желудочно-кишечного тракта. Целью настоящей работы была проверка этой гипотезы. Рентгенологически изучали перистальтику желудочно-кишечного тракта крыс в течение 25 ч после введения циклофосфана в дозе 1000 мг/кг, биоэквивалентной его миелоабляционной дозе для человека. Внутривнутрибрюшинное, подкожное или внутривнутрижелудочное введение циклофосфана замедляло желудочно-кишечный транзит сульфата бария. При подкожном введении циклофосфана этот эффект был умеренным, а при внутривнутрижелудочном — проявлялся полной остановкой транзита. Таким образом, моделирование на крысах миелоабляционной цитостатической терапии циклофосфаном сопряжено с развитием желудочно-кишечного стаза. Выявленные изменения могут способствовать поступлению в кровь продуктов жизнедеятельности кишечной микрофлоры и формированию эндотоксемии.

Ключевые слова: циклофосфан, миелоабляционная цитостатическая терапия, крысиная модель, рентгенография, желудочно-кишечный стаз

Вклад авторов: Т. В. Шефер — разработка экспериментальной модели, планирование исследования, экспериментальная часть, обработка и визуализация данных; Ю. Ю. Ивницкий — научный замысел, разработка экспериментальной модели, интерпретация результатов; В. Л. Рейнюк — организация экспериментальной части работы. Все авторы участвовали в обсуждении результатов, подготовке и редактировании рукописи статьи.

Соблюдение этических стандартов: исследование выполняли с соблюдением правил биоэтики, утвержденных Европейской конвенцией о защите позвоночных животных, используемых в экспериментальных и иных научных целях (ETS N 123).

✉ **Для корреспонденции:** Тимур Васильевич Шефер
ул. Лесопарковая, д. 4, г. Санкт-Петербург, 195043; schafer@yandex.ru

Статья получена: 14.12.2021 **Статья принята к печати:** 15.01.2022 **Опубликована онлайн:** 31.01.2022

DOI: 10.47183/mes.2022.001

Cyclophosphamide is used for the treatment of lymphoma, leukaemia, some solid tumours [1] and autoimmune disorders [2]. When carrying out myeloablative cytostatic therapy, the doses of cyclophosphamide are prescribed, which destroy the tumour, but cause fatal pancytopenia [3, 4].

Owing to subsequent allogeneic hematopoietic stem cell transplantation, these doses are an order of magnitude larger than the doses, used for conservative therapy [5], and exceed 120 mg/kg [6]. Early toxic effects of such doses of cyclophosphamide are manifested by asthenic and

emetic syndromes [7], limiting the drug tolerance. In rats, bioequivalent doses of cyclophosphamide (≥ 600 mg/kg) caused hyperammonaemia and symptoms, specific to the acute ammonium salt intoxication: ataxia, tremor, loss of reflexes, and seizure [8]. Increased permeability of the intestinal barrier could be the possible mechanism, underlying hyperammonaemia associated with acute cyclophosphamide intoxication [8–11]. Inhibition of intestinal peristalsis increases the permeability of the intestinal wall [12]. Thus, the study was aimed to assess the effects of the myeloablative dose of cyclophosphamide on gastrointestinal peristalsis.

METHODS

The study involved 24 male outbred albino rats with the body weight of 161–190 g, obtained from the Rappolovo laboratory animal nursery. The animals were treated in accordance with the Principles of Good Laboratory Practice, stated in the Order № 199n of the Ministry of Health of the Russian Federation, dated April 1, 2016 [13], and the requirements of the Guidelines for the Housing and Care of Laboratory Animals [14, 15]. Standard rat diet and ad libitum water access were provided. The day before the experiment the rats were deprived of food; however, access to water was not limited.

The rats were randomized into six groups, four animals per group. Water was administered in three control groups (intraperitoneal, subcutaneous, and intragastric routes). The freshly prepared aqueous cyclophosphamide solution in the amount of 10 mL/kg in a dose of 1000 mg/kg was administered in the corresponding three experimental groups. This was an absolutely lethal dose under either route of administration: all animals died within two weeks; in the case of intraperitoneal injection, the dose corresponded to 3.5 LD₅₀.

The 35% aqueous suspension of barium sulfate (10 mL/kg) was administered into the stomach of all rats using the gavage tube immediately after the cyclophosphamide administration. After 1, 3, 5, and 25 h the animals were placed in plastic pencil boxes, and the radiographic testing with the use of the Iconos R200 digital x-ray system (Siemens; Germany) was performed in a pairwise manner (experimental and control animals). X-ray images were assessed using the planimetric ruler by calculating the absolute and relative (percentage) values of the radiopaque shadow area in the stomach, duodenum, jejunum, cecum, descending colon, and rectum. The relative values other than zero or 100%, which were averaged for each group of animals, were ranked and assigned to one of the intervals (1–25, 26–50, 51–75, 76–99%), marked with various shades of grey; no shadow was marked with white, and the shadow of 100% of the injected barium mixture was marked with black. The data obtained were represented as a scheme.

RESULTS

An hour after the barium suspension administration to intact rats, a portion of the suspension passed from the stomach to the duodenum. After 3 h, the suspension was observed in the jejunum, and after 5 h it was also found in the cecum. Twenty-five hours after the start of the experiment the major portion of barium sulfate, found on the x-ray images, was in the descending colon and the rectum.

In the case of intraperitoneal administration of cyclophosphamide, barium suspension never reached the jejunum, and in the case of cyclophosphamide administered

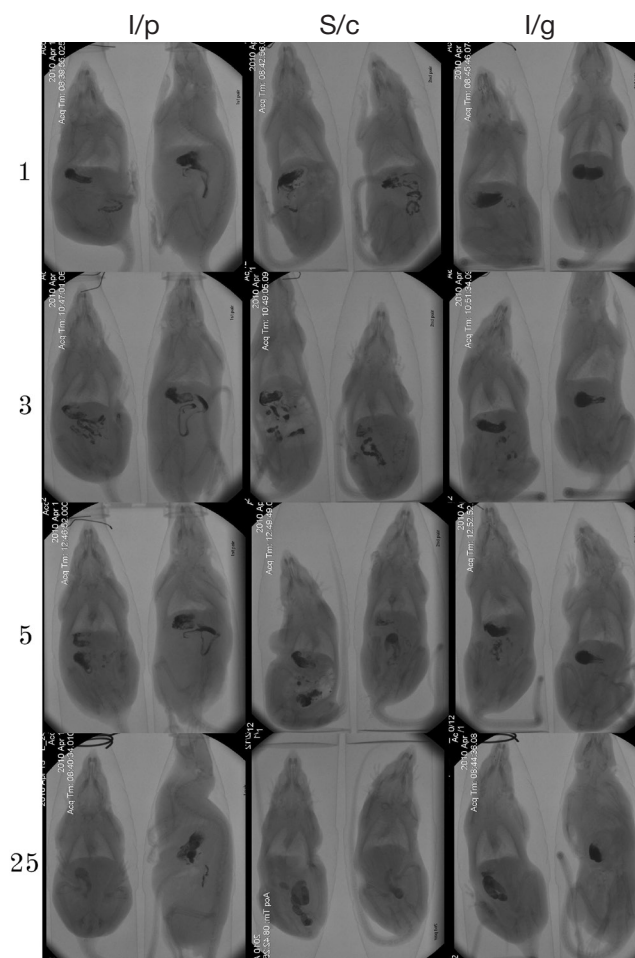


Fig. 1. X-ray radiography of rats performed at different times (specified on the left, hours) after administration of cyclophosphamide in a dose of 1000 mg (routes are specified on the top: i/p — intraperitoneal; s/c — subcutaneous; i/g — intragastric) and barium sulfate (i/g, immediately after cyclophosphamide administration). Control rats are shown on the left in each window

intragastrically, the suspension never left the stomach. Subcutaneous cyclophosphamide administration resulted in the less prominent slow-down of transit: after 3 h the radiopaque contrast medium left the stomach, however, after 25 h the medium did not reach the descending colon (Fig. 1, 2).

DISCUSSION

The development of gastrointestinal stasis in rats after cyclophosphamide administration is consistent with the earlier reported [16] slowing of gastric motility after the subcutaneous injection of cyclophosphamide in a dose of 50–200 mg/kg to rats. In the case of intragastric administration, the effect size could be due to the aldophosphamide (transport form of cyclophosphamide) hydrolysis in the acidic gastric contents with the formation of more active alkylating metabolites [17, 18].

In our study, the dose of cyclophosphamide corresponded to myeloablative dose for humans of 155 mg/kg [19]. Therefore, the data obtained clearly point to the possibility of developing gastrointestinal stasis in case of using cyclophosphamide to prepare the patients for the allogeneic hematopoietic stem cell transplantation.

Gastrointestinal stasis is a potentially fatal complication found in the intensive care unit patients [20, 21]. The condition increases the permeability of the intestinal barrier [22, 23], and results in the gram-negative bacterial lipopolysaccharides entering the bloodstream, developing systemic inflammation

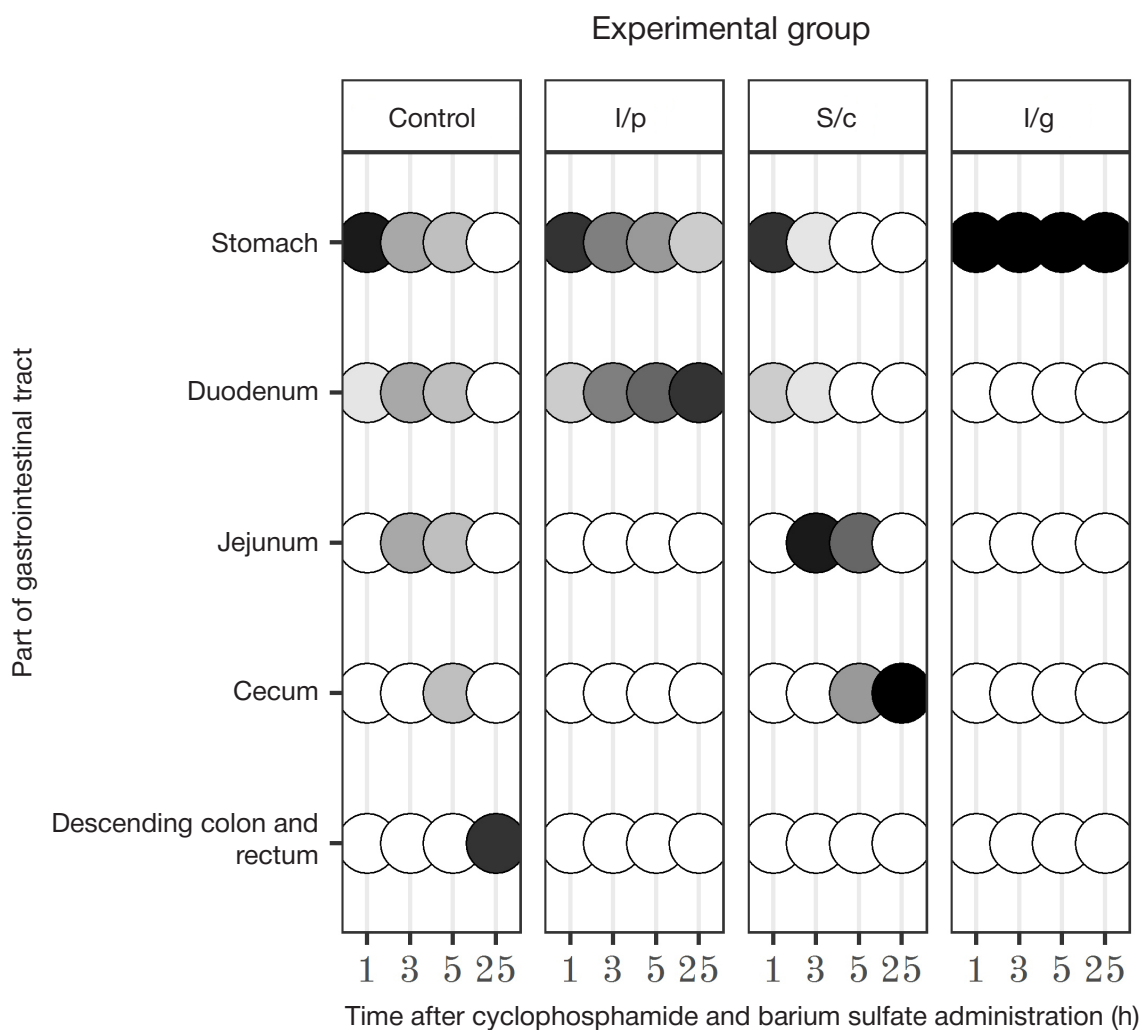


Fig. 2. Effects of cyclophosphamide administered in a dose of 1000 mg/kg on the barium suspension passage through the rat gastrointestinal tract. Shades of the circles are proportional to the percentage of the radiopaque shadow area in the corresponding section of the gastrointestinal tract: *black circles* — 100% of the administered barium sulfate; *white circles* — no barium sulfate

[24, 25] and sepsis [26]. Increased permeability of the intestinal barrier also results in the enhanced flux of toxic nitrogenous metabolites, such as ammonia, from chyme into the bloodstream. In rats, exacerbation of hyperammonaemia after the gavage with ammonium acetate against the background of acute cyclophosphamide intoxication leads to the rapid development of neurological disorders and significantly reduces the animals' life expectancy [27].

CONCLUSIONS

Modelling myeloablative cytostatic therapy in rats using cyclophosphamide results in gastrointestinal stasis. The changes in gastrointestinal peristalsis reported may contribute to the flux of the gut microbial products into the bloodstream and endotoxemia, and may be involved in the development of the cyclophosphamide early toxic effects.

References

- Emadi A, Jones RJ, Brodsky RA. Cyclophosphamide and cancer: golden anniversary. *Nature reviews. Clinical Oncology*. 2009; 6 (11): 638–47.
- Brodsky RA. High dose cyclophosphamide treatment for autoimmune disorders. *Scientific World Journal*. 2002; 28 (2): 1808–15.
- Kharfan-Dabaja MA, Reljic T, El-Asmar J, Nishihori T, Ayala E, Hamadani M, et al. Reduced-intensity or myeloablative allogeneic hematopoietic cell transplantation for mantle cell lymphoma: a systematic review. *Future Oncology*. 2016; 22 (12): 2631–42.
- Yee GC, McGuire TR. Allogeneic bone marrow transplantation in the treatment of hematologic diseases. *Clinical Pharmacy*. 1985; 4 (2): 149–60.
- Haioun C, Lepage E, Gisselbrecht C, Salles G, Coiffier B, Brice P, et al. Survival benefit of high-dose therapy in poor-risk aggressive non-Hodgkin's lymphoma: final analysis of Etude des lymphomes de l'Adulte study. *Journal of Clinical Oncology*. 2000; 18: 3025–30.
- Atilla E, Atilla PA, Demirer T. A review of myeloablative vs reduced intensity/non-myeloablative regimens in allogeneic hematopoietic stem cell transplantations. *Balkan Medical Journal*. 2017; 34 (1): 1–9.
- Legeza VI, Geleev ISh, Seleznyov AB. Emetic syndrome. Saint Petersburg: Foliant, 2005; 144 p. Russian.
- Ivnitsky JJ, Schäfer TV, Tyaptin AA, Rejniuk VL. Changes in the chemical composition of the blood and brain of rats under the conditions of modeling the myeloablation regimen of cyclophosphamide administration. *Toxicologicheskii vestnik*. 2019; 156 (3): 13–8. Russian.
- Schäfer TV, Rejniuk VL, Ivnitsky JJ. Ammonia redistribution from the gastrointestinal tract to general circulation after intraperitoneal

- injection of cyclophosphamide to rats. *Bulletin of Experimental Biology and Medicine*. 2010; 150 (8): 170–6. Russian.
10. Dore MP, Pes GM, Murino A, Quarta Colosso B, Pennazio M. Short article: small intestinal mucosal injury in patients taking chemotherapeutic agents for solid cancers. *European Journal of Gastroenterology & Hepatology*. 2017; 29 (5): 568–71.
 11. Schäfer TV, Ivnitsky JJ, Rejniuk VL. Cyclophosphamide-induced leakage of gastrointestinal ammonia into the common bloodstream in rats. *Drug and Chemical Toxicology*. 2011; 34 (1): 25–31.
 12. Ghareghani M, Reiter RJ, Zibara K, Fathadi N. Latitude, vitamin D, melatonin, and gut microbiota act in concert to initiate multiple sclerosis: a new mechanistic pathway. *Frontiers in Immunology*. 2018; 9: 2484.
 13. On Approval of the Rules of Good Laboratory Practice: Order of the Ministry of Health of the Russian Federation from April 1, 2016, No 199n. Moscow, 2016.
 14. Guidelines for the maintenance and care of laboratory animals. Rules of equipment of premises and organization of procedures: GOST 33215–2014. Moscow: Standartinform, 2016; 12 p. Russian.
 15. Guidelines for the maintenance and care of laboratory animals. Rules for the maintenance and care of laboratory rodents and rabbits: GOST 33216–2014. Moscow: Standartinform, 2016; 15 p. Russian.
 16. Visnovský P. The effect of cyclophosphamide and methotrexate on gastric emptying and secretion in rats. *Bratislavské lekárske listy*. 1992; 93 (2): 90–2. Slovak.
 17. Anderson LW, Chen TL, Colvin OM, Grochow LB, Collins JM, Kennedy MJ, et al. Cyclophosphamide and 4-hydroxycyclophosphamide/aldophosphamide kinetics in patients receiving high-dose cyclophosphamide chemotherapy. *Clinical Cancer Research*. 1996; 2 (9): 1481–7.
 18. De Jonge ME, Huitema AD, Rodenhuis S, Beijnen JH. Clinical pharmacokinetics of cyclophosphamide. *Clinical Pharmacokinetics*. 2005; 44 (11): 1135–64.
 19. Habriev RU, editor. Guidelines for the experimental (preclinical) study of new pharmacological substances. Moscow: Medicina, 2005; 832 p. Russian.
 20. Deane AM, Chapman MJ, Reintam Blaser A, McClave SA, Emmanuel A. Pathophysiology and treatment of gastrointestinal motility disorders in the acutely ill. *Nutrition in Clinical Practice*. 2019; 34 (1): 23–36.
 21. Frazer C, Hussey L, Bemker M. Gastrointestinal motility problems in critically ill patients. *Critical care nursing clinics of North America*. 2018; 30 (1): 109–21.
 22. Herbert MK, Holzer P. Standardized concept for the treatment of gastrointestinal dysmotility in critically ill patients—current status and future options. *Clinical Nutrition*. 2008; 27 (1): 25–41.
 23. Ukleja A. Altered GI motility in critically ill patients: current understanding of pathophysiology, clinical impact, and diagnostic approach. *Nutrition in Clinical Practice*. 2010; 25 (1): 16–25.
 24. Buchholz BM, Bauer AJ. Membrane Tlr signaling mechanisms in the gastrointestinal tract during sepsis. *Neurogastroenterology and Motility*. 2010; 22: 232–45.
 25. Shimizu K, Ogura H, Asahara T, Nomoto K, Morotomi M, Nakahori Y, et al. Gastrointestinal dysmotility is associated with altered gut flora and septic mortality in patients with severe systemic inflammatory response syndrome: a preliminary study. *Neurogastroenterology and Motility*. 2011; 23 (4): 330–5.
 26. Chapman MJ, Nguyen NQ, Deane AM. Gastrointestinal dysmotility: clinical consequences and management of the critically ill patient. *Gastroenterology clinics of North America*. 2011; 40 (4): 725–39.
 27. Ivnitsky JJ, Schäfer TV, Rejniuk VL. Promotion of the toxic action of cyclophosphamide by digestive tract luminal ammonia in rats. *ISRN Toxicology [Internet]*. 2011. Article ID 450875. Available from: <https://www.hindawi.com/journals/isrn/2011/450875/>.

Литература

1. Emadi A, Jones RJ, Brodsky RA. Cyclophosphamide and cancer: golden anniversary. *Nature reviews. Clinical Oncology*. 2009; 6 (11): 638–47.
2. Brodsky RA. High dose cyclophosphamide treatment for autoimmune disorders. *Scientific World Journal*. 2002; 28 (2): 1808–15.
3. Kharfan-Dabaja MA, Reljie T, El-Asmar J, Nishihori T, Ayala E, Hamadani M, et al. Reduced-intensity or myeloablative allogeneic hematopoietic cell transplantation for mantle cell lymphoma: a systematic review. *Future Oncology*. 2016; 22 (12): 2631–42.
4. Yee GC, McGuire TR. Allogeneic bone marrow transplantation in the treatment of hematologic diseases. *Clinical Pharmacy*. 1985; 4 (2): 149–60.
5. Haioun C, Lepage E, Gisselbrecht C, Salles G, Coiffier B, Brice P, et al. Survival benefit of high-dose therapy in poor-risk aggressive non-Hodgkin's lymphoma: final analysis d'Etude des lymphomes de l'Adulte study. *Journal of Clinical Oncology*. 2000; 18: 3025–30.
6. Atilla E, Atilla PA, Demir T. A review of myeloablative vs reduced intensity/non-myeloablative regimens in allogeneic hematopoietic stem cell transplantations. *Balkan Medical Journal*. 2017; 34 (1): 1–9.
7. Легеза В. И., Галеев И. Ш., Селезнев А. Б. Эметический синдром. СПб.: Фолиант, 2005; 144 с.
8. Ивницкий Ю. Ю., Шефер Т. В., Тяптин А. А., Рейнюк В. Л. Изменения химического состава крови и головного мозга крыс при моделировании миелоабляционного режима применения циклофосфана. *Токсикологический вестник*. 2019; 156 (3): 13–8.
9. Шефер Т. В., Рейнюк В. Л., Ивницкий Ю. Ю. Перераспределение аммиака из желудочно-кишечного тракта в общий кровоток при внутрибрюшинном введении циклофосфана крысам. *Бюллетень экспериментальной биологии и медицины*. 2010; 150 (8): 170–6.
10. Dore MP, Pes GM, Murino A, Quarta Colosso B, Pennazio M. Short article: small intestinal mucosal injury in patients taking chemotherapeutic agents for solid cancers. *European Journal of Gastroenterology & Hepatology*. 2017; 29 (5): 568–71.
11. Schäfer TV, Ivnitsky JJ, Rejniuk VL. Cyclophosphamide-induced leakage of gastrointestinal ammonia into the common bloodstream in rats. *Drug and Chemical Toxicology*. 2011; 34 (1): 25–31.
12. Ghareghani M, Reiter RJ, Zibara K, Fathadi N. Latitude, vitamin D, melatonin, and gut microbiota act in concert to initiate multiple sclerosis: a new mechanistic pathway. *Frontiers in Immunology*. 2018; 9: 2484.
13. Об утверждении Правил надлежащей лабораторной практики: Приказ Министерства здравоохранения Российской Федерации от 1 апреля 2016 г. № 199н. М., 2016.
14. Руководство по содержанию и уходу за лабораторными животными. Правила оборудования помещений и организации процедур: ГОСТ 33215–2014. М.: Стандартиформ, 2016; 12 с.
15. Руководство по содержанию и уходу за лабораторными грызунами и кроликами: ГОСТ 33216–2014. М.: Стандартиформ, 2016; 15 с.
16. Visnovský P. The effect of cyclophosphamide and methotrexate on gastric emptying and secretion in rats. *Bratislavské lekárske listy*. 1992; 93 (2): 90–2 (на словацком языке).
17. Anderson LW, Chen TL, Colvin OM, Grochow LB, Collins JM, Kennedy MJ, et al. Cyclophosphamide and 4-hydroxycyclophosphamide/aldophosphamide kinetics in patients receiving high-dose cyclophosphamide chemotherapy. *Clinical Cancer Research*. 1996; 2 (9): 1481–7.
18. De Jonge ME, Huitema AD, Rodenhuis S, Beijnen JH. Clinical pharmacokinetics of cyclophosphamide. *Clinical Pharmacokinetics*. 2005; 44 (11): 1135–64.
19. Хабриев Р. У., редактор. Руководство по экспериментальному (доклиническому) изучению новых фармакологических веществ. М.: Медицина, 2005; 832 с.
20. Deane AM, Chapman MJ, Reintam Blaser A, McClave SA, Emmanuel A. Pathophysiology and treatment of gastrointestinal motility disorders in the acutely ill. *Nutrition in Clinical Practice*. 2019; 34 (1): 23–36.
21. Frazer C, Hussey L, Bemker M. Gastrointestinal motility problems in critically ill patients. *Critical care nursing clinics of North America*. 2018; 30 (1): 109–21.
22. Herbert MK, Holzer P. Standardized concept for the treatment of gastrointestinal dysmotility in critically ill patients—current status and future options. *Clinical Nutrition*. 2008; 27 (1): 25–41.
23. Ukleja A. Altered GI motility in critically ill patients: current understanding of pathophysiology, clinical impact, and diagnostic approach. *Nutrition in Clinical Practice*. 2010; 25 (1): 16–25.
24. Buchholz BM, Bauer AJ. Membrane Tlr signaling mechanisms in the gastrointestinal tract during sepsis. *Neurogastroenterology and Motility*. 2010; 22: 232–45.
25. Shimizu K, Ogura H, Asahara T, Nomoto K, Morotomi M, Nakahori Y, et al. Gastrointestinal dysmotility is associated with altered gut flora and septic mortality in patients with severe systemic inflammatory response syndrome: a preliminary study. *Neurogastroenterology and Motility*. 2011; 23 (4): 330–5.
26. Chapman MJ, Nguyen NQ, Deane AM. Gastrointestinal dysmotility: clinical consequences and management of the critically ill patient. *Gastroenterology clinics of North America*. 2011; 40 (4): 725–39.
27. Ivnitsky JJ, Schäfer TV, Rejniuk VL. Promotion of the toxic action of cyclophosphamide by digestive tract luminal ammonia in rats. *ISRN Toxicology [Internet]*. 2011. Article ID 450875. Available from: <https://www.hindawi.com/journals/isrn/2011/450875/>.

- Emmanuel A. Pathophysiology and treatment of gastrointestinal motility disorders in the acutely ill. *Nutrition in Clinical Practice*. 2019; 34 (1): 23–36.
21. Frazer C, Hussey L, Bemker M. Gastrointestinal motility problems in critically ill patients. *Critical care nursing clinics of North America*. 2018; 30 (1): 109–21.
 22. Herbert MK, Holzer P. Standardized concept for the treatment of gastrointestinal dysmotility in critically ill patients—current status and future options. *Clinical Nutrition*. 2008; 27 (1): 25–41.
 23. Ukleja A. Altered GI motility in critically ill patients: current understanding of pathophysiology, clinical impact, and diagnostic approach. *Nutrition in Clinical Practice*. 2010; 25 (1): 16–25.
 24. Buchholz BM, Bauer AJ. Membrane Tlr signaling mechanisms in the gastrointestinal tract during sepsis. *Neurogastroenterology and Motility*. 2010; 22: 232–45.
 25. Shimizu K, Ogura H, Asahara T, Nomoto K, Morotomi M, Nakahori Y, et al. Gastrointestinal dysmotility is associated with altered gut flora and septic mortality in patients with severe systemic inflammatory response syndrome: a preliminary study. *Neurogastroenterology and Motility*. 2011; 23 (4): 330–5.
 26. Chapman MJ, Nguyen NQ, Deane AM. Gastrointestinal dysmotility: clinical consequences and management of the critically ill patient. *Gastroenterology clinics of North America*. 2011; 40 (4): 725–39.
 27. Ivnitsky JJ, Schäfer TV, Rejniuk VL. Promotion of the toxic action of cyclophosphamide by digestive tract luminal ammonia in rats. *ISRN Toxicology [Internet]*. 2011. Article ID 450875. Available from: <https://www.hindawi.com/journals/isrn/2011/450875/>.